# COLLECTION OF PUBLICATIONS

froggymouth

# Table of contents

Medical and Clinical Archives

Review Article ISSN: 2515-1053

# The role of biochemistry and neurophysiology in the re-education of deglutition

**Fellus Patrick***

Qualified specialist, Former Consultant for the Hospitals of Paris, France

## Abstract

The transition from suction-type deglutition to dentition-type deglutition should spontaneously occur between ages 3 and 4, but the genetic information is not always systematically expressed. The new program must then be engrammed by cortical or sub-cortical pathways.

## Introduction

Suction-type deglutition, the physiological mode for swallowing saliva in the young infant, is a praxis developed in the brainstem in utero.

It will remain physiological as long as the primary dentition is not established and mastication has not begun.

But beginning at age 4, a new deglutition program is naturally implemented via a subcortical pathway in 60% of children: dentition-type deglutition.

By the muscular force it generates, it promotes optimal growth of the maxillae [1].

But endogenous or innate factors can only provide the potential. "They will only be expressed if adequate exogenous conditions occur in a timely manner" (JP Changeux) [2,3]. Dawson Church states that "genes are activated or inactivated by our beliefs, emotions and attitudes."

There are two principal causes for the persistence of suction-type deglutition:

- the child has never had the opportunity to discover this new function
- the child has discovered it, but the limbic system, the gateway to engramming a new program, has not retained it, usually for psychological reasons (immaturity, thumb, pacifier, bottle, food too soft).

Most children requiring orthodontic treatment are found in the latter category.

The re-education of orofacial functions is consequently a necessity accepted by nearly all practitioners during orthodontic treatment, but it is necessary to properly understand both neuroanatomy and physiology to achieve reproducible and controllable results.

## Deglutition re-education

What strategy to implement?

- hope that the normalization of dental arches will lead to a change in function.

This is more feasible when wearing a removable retainer. The introduction of an element modifying proprioceptive sensations will automatically lead to a change in the afferent message, and consequently the efferent message [4]. The anatomical part having been modified by treatment, the correct program can install itself naturally, but without control, the new praxis may also remain dysfunctional. However, care must be taken with bonded retainers.

If the functional modification occurs, there are no negative consequences, but if the dysfunction remains, the pathological muscular force will be iatrogenic, no longer in the dental alignment but in the supporting bone tissue, which may be the source of subsequent periodontal disease.

- use of functional devices, usually at night, lingual envelope-type (NLE) devices intended to modify the lingual posture, Robin device, lingual elevator, Farrell or Bergensen-type gutters. However, the results remain haphazard, as long as the dysfunctional commands are not inhibited, aside from the fact that wearing these devices may be difficult for the child to deal with and rejected by the limbic system.

- consult professionals, such as speech therapists or physiotherapists.

The child must initially become aware of what he/she is doing, then the maneuver he/she should be doing, and its repetition should enable automation.

Eric Kandel, Nobel Prize in Medicine recipient in 2000 for his work on the transition from short-term to long-term memory, demonstrated in these cases an increase in the activity of neurotransmitters in the synapses involved, but we remain in the domain of short-term memory [5,6].

"Memory is not based on the properties of nerve cells as such, but on the nature of the connections between neurons and how they process the sensory information received": learning consists of tracing new circuits, and this plasticity occurs either by reconfiguring existing programs or creating new ones (Figure 1 and Table 1).

***Correspondence to:*** Fellus Patrick, Qualified specialist, Former Consultant for the Hospitals of Paris, France, E-mail: fellusp@wanadoo.fr

***Key words:*** *deglutition, short-term memory, procedural memory*

**Received:** June 09, 2017; **Accepted:** June 21, 2017; **Published:** June 24, 2017

**Table 1.** Reconfiguring existing circuits.

| | |
|---|---|
| Neurone 1 | Neuron 1 |
| Message nerveux | Nerve message |
| Neurone 2 | Neuron 2 |
| Nouvelles connexions | New connections |
| Forte transmission du message nerveux | Strong transmission of nerve message |
| Faible transmission du message nerveux | Weak transmission of nerve message |
| Connexion entre les neurones 1 and 2 | Connection between neurons 1 and 2 |

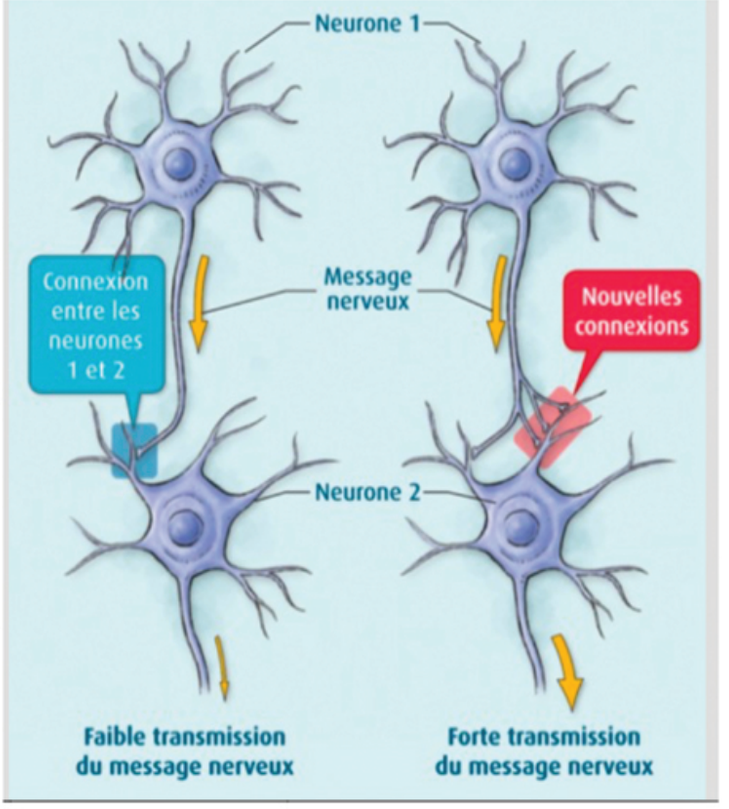


**Figure 1.** Eric Kandel Diagram.

Understanding the transition from short-term memory to long-term memory was clarified by the work of Kandell in Aplysia, by reconstituting a simplified neural circuit: a single sensory neuron connected to a single motor neuron:

- A slight stimulus releases neurotransmitters at the synapse, but the nucleus is not involved; this is short-term memory (weekly speech therapy sessions). This information will remain available only briefly.

- If the stimuli are repeated soon after, a dialogue occurs between the synapse and the nucleus to activate CREB* and produce a new protein, essential for the transition to long-term memory. This new CPEB** protein present in the synapse will function as a prion and permanently ensure the transmission of the message.

*CREB (Cyclic AMP Response Element-Binding Protein), a protein that activates the genes responsible for long-term memory. CREB 1 is the activator and CREB is the 2 inhibitor.

**CPEB: (Cytoplasmic Polyadenylation Element-Binding Protein), a transcriptional regulatory protein in the synapse which contributes to the stabilization of long-term memory.

## Creating new circuits

A highly emotional state can short-circuit normal constraints and produce a sufficient quantity of MAP-kinase* molecules, which will be sent to the nucleus to inactivate CREB-2** molecules and facilitate CREB-1** activation and direct imprinting of this experience in long-term memory

*MAP-kinase kinase: acts in conjunction with protein kinase A, to initiate long-term memorization.

- FroggyMouth is a device worn a rather short time, 15 minutes a day while watching television (a reward recognized by the limbic system), which will force the child to discover a new deglutition method via the sub-cortical pathway; thus, not by stimulating neurotransmitter activity, but by creating new synapses.

In fact, by no longer being able to close the lips, the child will be unable to swallow by suction, aspirating between the anterior and posterior mouth, triggering an abrupt and immediate reaction in the brainstem: find a new deglutition program.

The simultaneous contraction of the levator muscles of the mandible in a stable and comfortable dental occlusion with those of the soft palate and styloglossus will allow a peristaltic movement of the tongue (provided that the anatomical environment is compatible) and disconnect the tongue-lips synkinesis.

This new deglutition program will be immediately integrated into long-term memory by the creation of a new neural circuit.

But this is only the first step, which is necessary but not sufficient for the transition to automation.

## Automation

The child will then have two programs for swallowing saliva, and just as on a computer when there are two programs, it is the activation of one or another icon that initiates its execution (Figures 2 and 3).

The therapist should therefore monitor the resting posture for relaxation of the perioral muscles and dental occlusion upon swallowing.

Control by the trigeminal nerve, solicited at this step, will replace control by the facial nerve and inhibit the role of the latter.

This necessary inhibition of the faulty circuit is fundamental to automation of the correct program. Only FroggyMouth allows this double action. The trigeminal nerve, which also controls the respiration centers in the pontine tegmentum through its sensory nucleus, will promote restoration of nasal respiration, allowing the tongue to adopt a high posture posteriorly (the lingual dome).

"This dual posterior and occlusal functional necessity of the tongue, too often forgotten by re-educators of orofacial function, is likely one of the causes of the too-frequent failures of re-education" (Delaire) [7].

Similarly, contraction of the tensor tympani muscle, innervated by the trigeminal nerve, will allow ventilation of the middle ear by dilating the Eustachian tube, decreasing serous otitis problems Control may be transferred to the parents, who need to observe lip posture 5 times/day, and who then congratulate or correct the child (Figures 4 to 8). These two actions are not similar, involving cortico-cortical circuits that traverse the basal ganglia and cortico-cortical circuits that traverse the cerebellum [8].

Wearing FroggyMouth starting at age 3 has no contraindications.

## Conclusion

Early normalization of orofacial functions, regardless of the technique chosen, will enable a three-step preventive approach:



**Figure 2.** The suction-type deglutition icon is activated by the facial nerve: "My lips are contracted, my teeth do not touch."

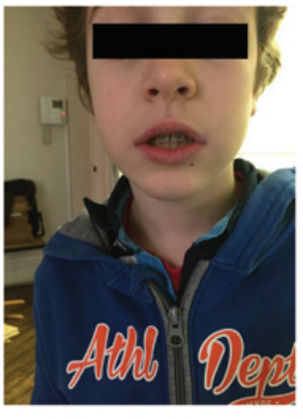

**Figure 3.** The dentition-type deglutition icon: "my lips are relaxed, my molars are in occlusion" is activated by the trigeminal nerve, whichallows not onlymolar occlusion but also the protection of the tongue from biting, due to the abundance of trigeminal nerve endings in its epitheliallining.

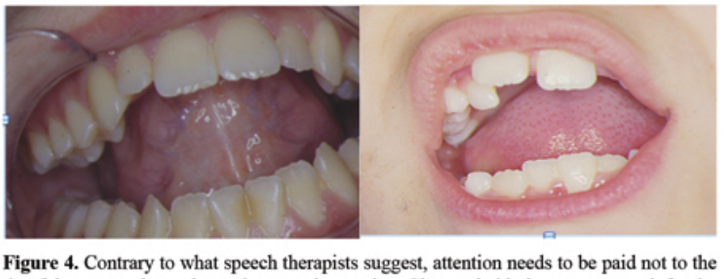

**Figure 4.** Contrary to what speech therapists suggest, attention needs to be paid not to the tip of the tongue, but rather to its posterior portion. Obsessedwith the sensorysearch for the retro-incisive papilla, the child risks raising the tip of the tongue, leading to lowering of the posterior portion, which will prevent the involvement of the styloglossus, the levator muscle of the lingual dome.

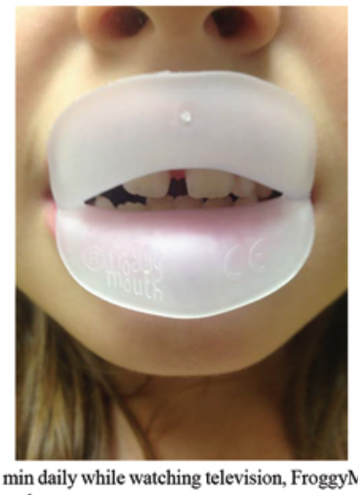

**Figure 5.** Worn for 15 min daily while watching television, FroggyMouth allows relaxation of all anterior facial muscles.

**Figure 6.** Spontaneous improvement of an incisor gap after wearing Froggy Mouth for one month.

**Figure 7.** Resumption of treatment with only Froggy Mouth after repetition of a previous orthodontic treatment.

**Figure 8.** Case treated by Gérard Altounian.

-prevent deformities from appearing,

-if they occur, prevent them from worsening,

## References


1. Patrick F (2003) Orthodontie précoce en denture temporaire Cdp.
2. Jean-Pierre C (1983) L'homme neuronal Fayard.
3. Gérard C (2010) Les oralités humaines Doin.
4. Gérard C (2015) Oralité du fœtus Sauramps Médical.
5. Arthur G (1996) Neurosciences. Piccin.
6. Eric K (2011) A la recherche de la mémoire. Odile Jacob.
7. Patrick F, Waddah S, Lalauze-Pol R (2016) De la dysfonction à la dysmorphose. Apport de Froggy mouth. Edition Orthopolis.
8. Fournier M, Girard M (2013) Acquisition and sustainment of automatic reflexes in maxillofacial rehabilitation. *Orthod Fr* 84: 287-294. [Crossref]

Dental, Oral and Craniofacial Research

Commentary ISSN: 2058-5314

# Suction deglutition to swallowing deglutition by cortical or subcortical networks

**Patrick Fellus***

Président of the French Pediatric Orthodontic Society, University Hospital Robert Debré Paris, France

Dropping the suction deglutition is necessary to build a physiological occlusion. Generally, it occurs by itself for 60% of children around four years old; it is in this sample of children that we will find the ones who will never need any orthodontic treatment.

When the child requires one, acquiring a good swallowing is going to reduce the duration of the treatment but also ensure the stability of the results and avoid the risk of relapse. This change of the swallowing program can be either done by the cortical or the subcortical way, but the results will be different.

As orthodontists, when we have to fix deformities they are mostly caused by a lack of balance between the opposing forces produced by the cheek muscles and the forces generated by the tongue. Whether orthopaedic treatment in deciduous dentition, orthodontic treatment in the mixed or permanent dentition, it is mandatory to reach at the end of the treatment a functional balance that will ensure the stability of the results.

Suction deglutition is a physiological function during the first years. It has a paleocortical origin, and the facial nerve controls it. But it becomes archaic when the full set of teeth is in place, and when mastication appears. If suction-swallowing habit continues, the forces exerted by the labio-jugal muscles will disturb physiological growth and will lead to various skeletal disorders in the three directions.

A new swallowing program, controlled by the trigeminal nerve is therefore required. It appears spontaneously by a subcortical action around four years old for 60% of children by using a pre-existing neurological wiring. It will be among those children that we can find the 50% of them who will never need any orthodontic treatment. If it does not happen by itself, then, like in a computer, a new program will have to be downloaded.

It is what the practitioner or the speech therapist is going to do through series of exercises to code a new praxis. But even with an accurate cooperation of the child, it is long and complicated.

"Memory is based (…) on the nature of the connection between neurons and the way they use the sensorial information they receive. "

According to Eric Kandel, Nobel Price of Medicine in 2000, when this action comes from the cortical area we have a stimulation of neurotransmitters in our synapses, and when it comes from the subcortical area we have a creation of new synapses. The swallowing rehabilitation cannot be based on the control of voluntary movements but on the stimulation of the subcortical area.

Froggy mouth is a new appliance which helps young children from 3 - 4 years old to use the best swallowing method for a toothed patient through the subcortical way and not anymore the suction deglutition method (Figure 1).

This Appliance is based on the idea of no connection between the lips and the tongue, which is the exact definition of suction deglutition (Figure 2).

**Figure 1.** Three years old girl wearing Froggy mouth.

**Figure 2.** Result after 2 weeks.

***Correspondence to:*** Patrick Fellus, Président of the French Pediatric Orthodontic Society, University Hospital Robert Debré Paris, France, **E-mail:** fellusp@wanadoo.fr

**Received:** May 10, 2016; **Accepted:** June 11, 2016; **Published:** June 14, 2016

**Figure 3.** Result 15 Min per day with froggy mouth.

Froggy mouth is not placed inside the mouth but between the lips. It will prevent the upper one from touching the lower one, thus, it avoids the negative pressure that was applied inside the mouth thanks to a water-tight joint around the lips. Indeed, it will force the child to find by himself a new way for the deglutition in the lower part of his brain by raising the upper back of the tongue to the palatal bone.

This action will lead to a eumorphic development of the dental arch.

This appliance has to be worn 15 minutes per day and should not be worn during the night like « trainers ». Indeed, the quality of the sleep is critical for young children. It must be worn in front of a screen (TV or movie/series in a computer screen) to catch the attention of the patient fully and then stimulate his neuron circuits which are related to automatic functions (Figure 3).

This Appliance is only an auxiliary that you will be able to use in your treatments whatever the techniques you apply (functional or mechanical) during few weeks. It is obvious that results will be achieved much faster if the muscles and the appliance are both working in the same way rather than if they are fighting against each other.

It will not only reduce the length of your treatments but much more important; it will ensure its durability when the treatment will be over and then reduce the risk of relapse.

Froggy mouth is perfectly adapted to young children and it can even be used alone if the deformity is slight: the simple fact to rebalance the functions will allow a spontaneous correction of slight deformity when the child still has deciduous teeth.

- This Appliance is based on the principle of the absence of connection between the lips and the tongue, which is the exact definition of suction deglutition.
- This appliance is not placed inside the mouth but between the lips to prevent the upper lip from touching the lower one. Thus it stops the negative pressure to be applied inside the mouth, thanks to a water-tight joint around the lips.
- This will force the child to spontaneously find a new way for deglutition.

At rest the lips are not in contact, the teeth are in occlusion, the trigeminal nerve is the leader. The new swallowing program is used if the lips are in contact the teeth are not closed the facial nerve is the leader the chils swallow with the suction deglutition program.

## Conclusion

This little girl of three years old had been wearing Froggy Mouth for only two weeks. She is perfectly at ease with it. She is not dribbling, her face and muscles are relaxed, and the deformity is less significant than the beginning.



# How to upgrade from suction deglutition to swallowing deglutition trough cortical or subcortical networks

**Dr. Patrick Fellus**
**France**

The deformities that orthodontists have to cure are mostly caused by a lack of balance between the opposing forces produced by the cheek muscles and the forces generated by the tongue.

Whether orthopedic treatment in the deciduous dentition, orthodontic treatment in the mixed or permanent dentition, it is necessary to reach at the end of any treatment a functional balance that will ensure the stability of the results.

The transition from sucking deglutition to the physiological deglutition takes place spontaneously for 60% of the children between the age of three and a half and four by a subcortical activation of the a pre-existing neurological wiring which have just matured.

Suction deglutition was a physiological function during the first years. It has a paleocortical origin, and the facial nerve controls it. But it becomes archaic when the full set of teeth is in place, and when the mastication appears.

- If suction-swallowing habit continues, the forces exerted by the labio-jugal muscles will disturb the physiological growth and will lead to various skeletal disorders in the three dimensions of space.

If it does not happen by itself, then, like in a computer, a new program will have to be downloaded, controlled by the trigeminal nerve

It is what the practitioner or the speech therapist is going to do through a series of exercises to code a new praxis. But even with an accurate cooperation of the child, it is a long and complicated process because it need a participation of the cortical brain.

According to Eric Kandel, Nobel Price of Medicine in 2000, when this action comes from the cortical area we have a stimulation of neurotransmitters in our synapses, but when it comes from the subcortical area we have a creation of new synapses.

The swallowing rehabilitation must not be based on the control of voluntary movements but on the stimulation of automatic movements:

- Froggymouth is a new appliance which helps young children at the age of 3 - 4 years to use the best swallowing method for a toothed patient through the subcortical way and not anymore the suction deglutition method.

*Figure 1.*

- This Appliance is based on the idea of deconnection between the upper lip and the lower one.

Froggymouth is not placed inside the mouth but beetwen the lips (**fig.1**).

It will prevent the upper one from touching the lower one. So, it is impossible to create the negative pressure which is necessary during suction deglutition thanks to a water-tight joint around the lips. Indeed, it will force the child to find by himself a new way for the deglutition, in the lower part of his brain, by raising the upper back part of the tongue to the palatal bone when the teeth are in occlusion.

The activity of the seventeen muscles of the tongue against the internal side of the teeth allows an optimal stimulation of the transversal and antero-posterior growth of the dental arch.

This appliance has to be worn 15 minutes per day and should not be worn during the night like a trainer as the quality of the sleep is so important for young children. Froggymouth must be worn in front of a TV screen to have a good orientation of the head and to catch the attention of the patient. It will stimulate his neuron circuits, which are related to the subconscious functions. At rest the lips are not in contact, the teeth are in occlusion and the trigeminal nerve control this program.

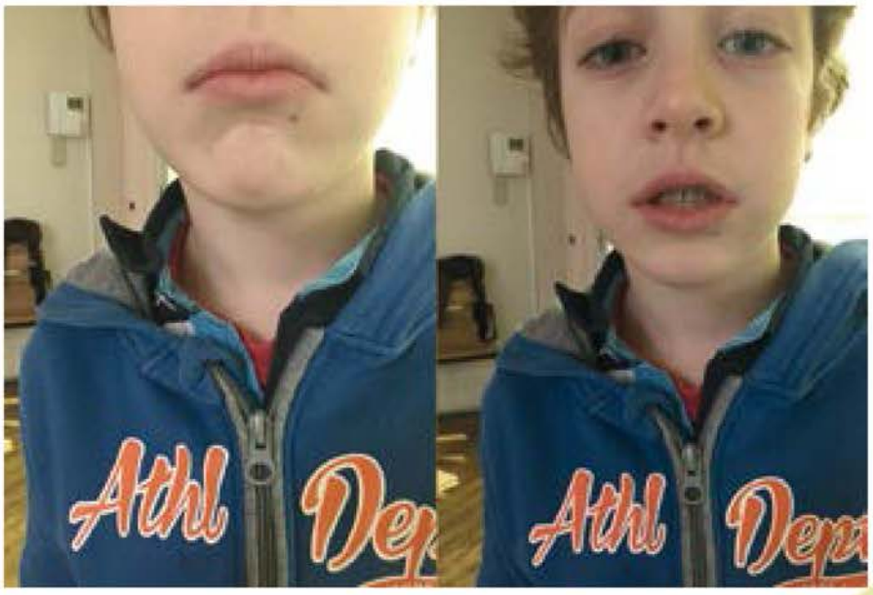

***Figure 2.*** *Position of the lips during suction déglutition and during swallowing deglutition.*

At the opposite, when the lips are closed, the teeth will not be in contact, and the facial nerve will be the leader, the child will use the old swallowing pattern.

This Appliance is only an auxiliary that you will be able to use during your treatments for a few weeks whatever the techniques you apply (functional or mechanical).

***Figure 3.*** *Case treated by G.Altounian.*

It is obvious that results will be achieved much faster if the muscles and the appliance are both working in the same direction rather than if they are fighting against each other.

Froggy mouth is perfectly adapted to young children and it can even be used alone if the deformity is slight:

- The simple fact to rebalance the functions will allow a spontaneous correction of slight deformity when the child still has deciduous teeth.

***Figure 4.*** *This little girl of three years old had been wearing Froggy Mouth for only two weeks. She is perfectly at ease with it. She is not dribbling saliva, her face and muscles are relaxed, and the deformity is less significant than it was at the beginning.*

## CONCLUSION

Froggymouth will not only reduce the length of your treatments but much more important; it will ensure its durability when the treatment will be over and then reduce the risk of relapse.

# Sucking and swallowing

P. Fellus

Specialist in dentofacial orthopedics

Doctor of odontologic science
Consultant, Robert Debré University Hospital Center, Paris, France

ABSTRACT

*Absence of bilabial contact rules out any possibility of using negative pressure inside the oral cavity. The patient cannot use suction gulp to swallow saliva. Molar occlusion creates a lingual dome that can act as a functional matrix, restoring nasal breathing.*

*Froggy Mouth® is a small removable appliance particularly adapted to young children. It is worn 15 minutes a day in front of the television, thus conserving sleep quality.*

*It stimulates the neural circuits governing automatic but not voluntary movement.*

KEY-WORDS

*Suction-gulp, swallowing in dentate subjects, neural circuits of voluntary movement, neural circuits of automatic movement, Froggy Mouth*

Corresponding author: Patrick Fellus – 18, Rue de Condé – 75006 Paris, France fellus@orthodontiepediatrique.com

Article received: July 18, 2014. Accepted for publication: August 24, 2014.

While, during gestation, the fetus was in an aquatic environment at constant temperature and with continuous nutrient input. Delivery propels it into an aerial environment in which it must breathe and feed by itself. Fortunately, it has been training *in utero* since the 11th week, swallowing amniotic fluid, to develop a functional unit enabling it, in the first minutes of life, to find the breast and meet its nutritional needs.

This swallowing program, of paleocortical origin, remains physiological as long as the mouth has no teeth[2,3]; the tongue fills the oral cavity completely, in contact laterally with the cheeks and anteriorly with the labial mucosa. The airtight joint required for suction is created by contracting the lips. Once the dental system, however, develops, alternating unilateral mastication begins slowly to mature in successive stages, from soft to compact foods[1].

Persistent suction-gulp slows down these developments and labio-jugal muscle activity impairs physiological growth, causing variable 3-dimensional skeletal disorders.

A new swallowing program is therefore required, and develops spontaneously in young children, 60% of whom discover a new way of swallowing by 4 years of age, and will be among those 50% of children who never require orthodontic treatment.

They spontaneously discover the need for a high posterior lingual dome position, achieved by tensing the styloglossus, a muscle which also narrows the tongue, bringing the apex of the tongue into a physiological area without sensory reference. There is thus posteriorization of the baseline motor configuration, from exofacial to endofacial.

If this does not happen naturally, then, like with a computer, a new program will have to be installed[3]. This is what the practitioner or speech-therapist does, in a series of codified exercises to program a new praxis[6] in the short-term memory circuits. This then has quickly to become long-term. The child at this point has two swallowing programs, as, just like in a computer, a program cannot actually be deleted from the hard drive or cortex. The old program just has not to be used: the child should stop clicking on that icon but rather on the new one. The old icon, is for “My lips are contracted” (Fig. 1), and the new one means “my lips are relaxed (Fig. 2) and my back-teeth are touching”. If, when the child swallows saliva, the lips are contracted by facial nerve activity, the old program will automatically be switched on. If, on the other hand, the lips are relaxed and the teeth closed together under trigeminal control, the right program will be launched.

Figure 1: Lips contracted, and depressor labii inferioris and chin also: the suction-gulp program will be launched.

Figure 2: Lips apart; a tight lip joint is impossible and the new program will govern the swallowing sequence.

Thus, swallowing rehabilitation needs to be based not on control of voluntary movements but on stimulating the subcortical connections that are functional in all children by 4 years of age and on activating the inhibition of the suction-gulp circuit[5]. This approach is founded on the work of Eric Kandel, 2000 winner of the Nobel Prize for medicine.

Figure 3: Froggy Mouth®, worn for 15 minutes a day in front of the TV, facilitates automatic acquisition of the new swallowing program which is spontaneously established in 60% of children by the age of 4 years.

Froggy Mouth® is a device that helps choose the right icon (Fig. 3). It is placed sagittally between the lips and teeth, separating the upper from the lower lip. Absence of bilabial contact prevents any negative pressure within the oral cavity and thus any use of suction-gulp to swallow saliva.

Initially, it should be worn for 15 minutes a day, in front of the TV or computer screen, so as to activate the neurologic circuits governing automatic movement under the control of the trigeminal nerve, which also controls the respiratory centers[4], promoting recovery of nasal breathing. This very short daily practice does not interfere with the child's sleep, which is very important, and the playful activity that continues during the exercise acts as a reward from the point of view of the limbic system.

The approach is just as well suited for older children: acquisition may take longer after the physiological age.

But none of this can happen unless suction habits, which are physiological during the first months of life, have disappeared (Figs. 4, 5).


Figure 4: a) Wide incisor gap caused by use of a dummy. b) Spontaneous improvement after withdrawal of dummy. c) Swallowing rehabilitation provides complete correction of dysmorphosis. d) Occlusion, with no further intervention, 3 years later.

a b

Figure 5: a) Retromandibulism in an inveterate thumb-sucker, aged 3; b) end of treatment.

This is why it is important to be sure than baby-bottles and dummies have been withdrawn.

During the first year of life, a dummy can significantly reduce the risk of sudden infant death and facilitate sleeping, but should ideally be withdrawn by 1 year of age. A Swedish study published 30 years ago reported that use of dummies beyond 2 years of age impaired communication and language acquisition.

But we should perhaps go further and analyze the psychological impact of dummies. It is not the same for thumb-sucking: many *in utero* ultrasound images show that digital sucking is discovered early on; during childhood, children manages this body part themselves, on the road to *autonomy*..

Dummies, in contrast, are foreign bodies introduced by parents or care-givers, and are integrated psychologically as part of the child's outside world.

Worn-out dummy, dummy lost: the child, to get satisfaction, is *dependent* on a third party (here, a parent).

Dummies should have disappeared by 2 years of age at the latest, as should feeding bottles. Withdrawal from thumb-sucking, on the other hand, can await 4 years.

Beyond this age, withdrawal can be helped by wearing a very simple intra-oral device which, by altering the afferent message reaching the brain, enables a new efferent message to be formed. In 95% of cases, thumb-sucking is a question of habit, and the present protocol enables spontaneous cessation without frustration, and is thus highly preferable to behavioral protocols requiring grids to be filled out with alternating suns and clouds – with feelings of guilt liable to arise in case of failure. For the 5% of children who go on sucking their thumbs despite wearing the device, sucking is not a "habit" but a "need"; this symptom may not always be serious, but it is always significant. A psychologist or child-psychiatrist should be systematically consulted in these rare cases, to have a differential diagnosis between delayed affective development and a more severe issue of psychological origin.

## Conflicts of interest

The author is President of Orthopolis SAS, which holds the patent for Froggy Mouth.

## REFERENCES

1. Couly G. Les oralités humaines. Doin, 2010.
2. Deffez JP, Girard C, Fellus P. Rééducation de la déglutition salivaire. Éditions CdP, 1995.
3. Fellus P. Orthodontie précoce en denture temporaire. Éditions CdP, 2003.
4. Guyton A. Basic neurosciences: anatomy and physiology. Philadelphia: Saunders Company, 1991.
5. Kandel E. À la recherche de la mémoire. Une nouvelle théorie de l'esprit. Odile Jacob Sciences, 2007.
6. Piaget J. Les praxies chez l'enfant. Revue de neurologie 1960;102(6):551-566.

Open Access
Online Journal of
Dentistry & Oral Health
Iris Publishers

Opinion



# A Simplified Approach to Rehabilitation of Swallowing: Labiotherapy

**Patrick Fellus***

*Président of the French Pediatric Orthodontic Society, University Hospital Robert Debré Paris, France*

***Corresponding author:** Patrick Fellus, Président of the French Pediatric Orthodontic Society, University Hospital Robert Debré Paris, France Email: fellusp@wanadoo.fr

**Received Date:** September 19, 2018
**Published Date:** Septembert 26, 2018

## Opinion

Functional rehabilitation is now part of the treatment of dysmorphoses requiring orthodontic treatment.

But it is actually all practitioners who should be concerned with acquiring a myofunctional balance in the oral zone. Joint prostheses, implants, complete prostheses, periodontal health all these daily acts absorb muscle forces generated by oral praxies.

Abandoned during the initial training, these functional rehabilitation procedures, which are time-consuming and maltreated by the nomenclature, are insufficiently integrated into the daily practice of general practitioners.

The contribution of functional educators [1] to wear all night in addition to a series of exercises, has allowed the gradual integration of this approach in the treatment plans for complete rehabilitation of the masticatory system, without the need the help of speech therapists also facing the difficulty of re-education of swallowing.

Whereas the transition from sucking swallowing to swallowing of the subject type is completely natural and without difficulty for 60% of children between the age of three and four years with the arrival of chewing in a complete dentition.

"But we found that the maintenance of the intake by sucking in the child maintained a certain delay in the establishment of the praxis of chewing" [2] and the acquisition of the swallowing type subject toothed.

Teats, baby bottles and too soft food do not facilitate the installation of a genetic program that is ours. The innate factors put in place only potentialities: "they will express themselves only if the adequate exogenous conditions intervene in a timely manner" [3].

The practitioner must therefore take care of the withdrawal strategy with the child and his parents to inhibit dysfunctional praxies and be able to facilitate the establishment of physiological praxies. At this age, neuronal maturity does not allow voluntary control of the lingual musculature required for conventional speech therapy, which has led us to consider a more suitable approach to young children: labiotherapy. The control of the labial dynamics is much easier than the control of the lingual dynamics, and it is the starting point of a series of sensory-motor modifications that the works of Eric Kandel and the new data of the neuro sciences to understand:

"Learning leads to a change in the strength of synaptic connections between specific cells of the nervous circuit that convey the behavior".

Learning will consist in tracing new circuits, this plasticity will be done either by remodeling existing programs or by creating new ones. But entrusted to speech therapists or kinesitherapists, even specialized, modification of existing neural circuits will require a modification of neurotransmitters during a dialogue between synapse and nucleus which is always long and tedious.

However a strongly emotional state can bypass normal stresses and create new synapses allowing the direct impression of this experience in long-term memory: if you had a car accident 20 years ago you will always remember that it was raining that day, that you were driving such a car brand and even that you wore such clothes. And yet you have never consciously and regularly repeated this episode [5].

In the same spirit the use of a device preventing the coaptation labial and forcing the child to discover by himself the new mode of swallowing (Froggymouth) has shown its effectiveness and simplicity. The child will be placed 15 minutes a day in front of a television screen that will grab his attention so he will not realize the impossibility of performing the intraoral vacuum and swallow with his usual program. Stress in the brainstem will force him to choose another pattern. The lips not touching any more, it will spontaneously tighten the teeth which will allow the elevation of the posterior part of the tongue against the palatal vault. The

control of this dynamic will be supported by the trigeminal nerve and will inhibit the action of the facial nerve that controls the labial dynamics. We will thus obtain an almost immediate acquisition of the new praxis (Figure 1-3).

**Figure 1:** froggymouth prevent a bilabial contact and the sucking deglutition

**Figure 2 :** The icon of suction-swallowing is activated by the facial nerve: "my lips are contracted, my teeth do not touch".

**Figure 3:** The dented subject swallowing icon: "my lips are relaxed, my molars in occlusion".

The dented subject swallowing icon: "my lips are relaxed, my molars in occlusion" is activated by the trigeminal nerve that will allow not only the molar occlusion but also the protection of the tongue against the bites thanks to the richness of the trigeminal nerve endings of its epithelial cover [6].

The icon of subject-type swallowing: "my lips are relaxed, my molars in occlusion" is activated by the trigeminal that also controls the centers of respiration in the pontic tegmentum by its sensory nucleus will promote a restoration of nasal breathing.

The therapist should therefore monitor the resting posture to relax the perioral musculature and dental occlusion at the time of swallowing. "This double posterior lingual and occlusal functional necessity, too often forgotten by oro-facial rehabilitation therapists, is probably one of the causes of the too frequent failures of re-education" [7].

As in a game of falling dominoes the simple fact of re-educating the lips (2 orbicular) will lead by reorganization of the sensitivo-motor areas, a re-education of the 17 muscles of the tongue which will lead to a reeducation of the breathing and a reeducation of the muscles Pharyngeal cycling that will lead to a reeducation of the tympanic musculature. Long underestimated the role of glial cells is now put forward to explain these effects by a bottom-up approach directly targeting the deficit or abnormality, but not requiring the taking awareness of this deficit or anomaly. Intended initially for children receiving orthodontic treatment, the effectiveness of Froggymouth also allows adults to be rehabilitated as long as neurogenesis persists [8,9].

## References


1. Changeux Jean-Pierre (1983) L'homme neuronal Fayard.
2. Couly Gerard (2010) Les oralités humaines Doin.
3. Couly Gerard (2015) Oralité du fœtus Sauramps Médical.
4. Fellus Patrick (2003) Orthodontie précoce en dentadura temporal Cdp.
5. Fellus Patrick, Sabouni Waddah, Lalauze-Pol (2016) De la dysfonction à la dysmorphoses Apport de Froggymouth Edición Orthopolis.
6. Froger J, Laffont I, Dupeyron A, Perrey S, Julia M (2017) La plasticité cérébrale Sauramps Medical.
7. Jean Delaire (1996) After Nasal Breathing.
8. Kandel Eric (2011) A la recherche de la mémoire. Odile Jacob.
9. La Recherche, Hors Serie N°22: la mémoire: neurogènes et souvenirs, synapses et protéines, émotions et amygdale.

Japan Journal of Medicine
2018; 2(1): 326 - 329 . doi: 10.31488/jjm.1000134

Review

# How biochemistry and neurophysiology are involved in the re-education of deglutition

Patrick Fellus*
Président of the French Pediatric Orthodontic Society, University Hospital Robert Debré Paris, France
Corresponding author: Dr. Patrick Fellus, Président of the French Pediatric Orthodontic Society, University Hospital Robert Debré Paris, France, E-mail: fellusp@wanadoo.fr

Received: December 02, 2018; Accepted: January 20, 2018; Published: January 30, 2018

## Abstract

The transition from suction-type deglutition to dental-type deglutition needs to occur spontaneously between 3 and 4 years of age, but the genetic information for this is not expressed systematically. When this transition does not occur spontaneously, the new program needs to be engrammed by conscious actions or by stimulation of the sensory-motor areas.

Keywords: deglutition, short-term memory, procedural memory

## Prolegomenon

Suction-type deglutition, which is a physiological mode for swallowing saliva in young infants, is an automatization that develops at the level of the brainstem in utero. Dietary alteration progressively integrates a cortical activity for control of the programming of deglutition, although this first mode of deglutition remains physiological as long as the primary dentition has not come in and mastication has not begun. Beginning at four years of age, the implementation of mastication sets off a new programming of deglutition in 60% of children referred to as dentition-type deglutition. It takes place naturally (bottom-up approach), stimulating the sensory-motor areas: "The anatomical components are the same but the programming of deglutition is reconfigured" [4]. It involves developmental plasticity. By way of the muscle forces that it generates, this new mode of deglutition promotes optimal growth of the maxilla [5].

But the endogenous or innate factors only give rise to potentialities. "It is only expressed when adequate exogenous conditions occur in a timely manner" (JP Changeux) [1]. Dawson Church stated that "genes are activated or inactivated by our beliefs, our emotions, and our attitudes".

Two main causes for the persistence of suction-type deglutition: the child has never had the opportunity to discover this new mode of functioning as their dietary habits did not elicit mastication; the child discovered it but the limbic system, a prerequisite for engramming a new program, did not retain it, generally for psychological reasons (emotional immaturity, continued thumb sucking, use of a pacifier or bottle). Most of the children requiring orthodontic treatment are found in the latter category. Re-education of orofacial functions (plasticity linked with experience) is hence a necessity recognized by nearly all practitioners when undertaking orthodontic treatment, but it is necessary to properly understand the neuroanatomy as well as the physiology to achieve reproducible and controllable results.

## Re-education of Deglutition

### What strategies should be implemented?

1) Hope that normalization of the dental arches will lead to an alteration in function. This is all the more feasible when using a removable retainer. Indeed, the use of an item that alters the proprioceptive feelings will automatically lead to an alteration of the afferent signal and hence facilitate alteration of the efferent signal. Alteration of the anatomical setting by the treatment will allow the program to engage naturally, although without monitoring the new praxis could well remain dysfunctional. However, care must be taken with fixed retainers.

If functional alteration occurs, there are no adverse consequences, although if there is dysfunction, the pathological muscle forces will be iatrogenic not only at the level of the alignment of the teeth blocked by the wire but also at the level of the supporting bone tissues, and this can be the origin of a pathology that ultimately affects the periodontium. Uncontrolled movements of the roots of

the lower incisors can also occur in a short amount of time [11].

2) Use of a functional devices, generally at night, aimed at alteration of tongue posture: LEN type, Robin device, tongue elevator, Farrell or Bergensen-type gutters, although the outcomes remain inconsistent as long as the dysfunctional commands are not inhibited, although wearing of such devices (between 12 and 14 hours per day) could be a difficult experience for the child and rejected by the limbic system. Being worn for an extended period of time is all the more unnecessary as the period of encoding is diurnal, only the consolidation is nocturnal. "Functional brain imaging has revealed electrical reactivation during sleep, as if the brain replays the daytime neuronal activities"[10].

3) Consultation with professionals such as speech therapists or physiotherapists (top-down approach). First of all, the child needs to become aware of the movement that they make and the movement that they should be making, the repetition before automization can occur. Knowing what one needs to do is, however, not enough to be able to do it (e.g., consider the difficulties with learning a new sport). This is a deliberate learning process by repetition and sensory-motor adjustment.

Eric Kandel, Nobel laureate in Medicine in 2000 for his work on short- and long-term memory, has shown that in the latter case there is an increase in the activity of neurotransmitters at the level of the synapses involved, but what we are dealing with here is short-term memory [8].

**Schema Eric Kandel**

"Memory is not based on the properties of the nerve cells as such, but on the nature of the connection between neurons and how they process the sensory information received". Learning consists of tracing new circuits, and this plasticity arises either due to reconfiguration of existing programs or by the creation of new ones.

**Reconfiguration of existing circuits**

Understanding of the conversion of short-term memory into long-term memory was elucidated by the work of Kandel on Aplysia:

1. Light stimulation releases neurotransmitters at the level of the synapse, while the nucleus is not involved in short-term memory (e.g., weekly speech therapy sessions). This information only remains available for a relatively short period of time.

2.When the stimulations are repeated in a short period of time (e.g., several weekly sessions and daily exercises at home), a dialogue is generated between the synapse and the nucleus that activates CREB* and it produces a new protein indispensable for the transition to long-term memory. This new protein, CPEB**, in the synapse functions as a prion and ensures transmission of the message in a permanent manner.

**Creation of new circuits**

In parallel, a highly emotional state can short-circuit the normal constraints and produce a sufficient quantity of MAP-kinase* molecules that are then sent to the nucleus to inactivate CREB-2** molecules, thereby promoting activation of CREB-1** and direct imprinting of this experience in the long-term memory. *MAP-kinase: acts in conjunction with protein kinase A to initiate long-term memorization.

Froggy Mouth® is a device that, when worn for 15 minutes per day over a relatively short period of time and while watching television (a reward recognized by the limbic system), forces the child to discover a new way of deglutition by the subcortical route; thus, not by stimulation of the activity of neurotransmitters but by the creation of new synapses. Indeed, by not being able to purse their lips, they are unable to swallow by suction, aspirating between the front of the mouth and the rear of the mouth, triggering an abrupt and immediate reaction at the level of the brainstem: find a new program for deglutition.

Faced with this new situation, the child employs the patterns that they have available. If they do not have a pattern suitable for the new situation, they will need to generate one. This amounts to incidental and nearly immediate learning.

The concurrence of the contraction of the levator muscles of the mandible in a stable and comfortable dental occlusion with those of the soft palate and the styloglossus allows peristaltic movement of the tongue (provided that the transverse and vertical anatomical environment are compatible) and disconnection of the lip-tongue synkinesis. This new program of deglutition immediately becomes integrated into long-term memory by the creation of a new neuronal circuit. It is, however, only the first step, which is necessary but not sufficient to transition to automatization.

**Automatization**

The child then has two programs available to swallow saliva. Just like on a computer when two programs are available, it is the activation of one or the other icon that initiates its execution. The therapist, therefore, needs to monitor the posture at rest to obtain relaxation of the perioral muscles and dental occlusion upon deglutition. The control by the trigeminal nerve that is solicited at this step substitutes for the control by the facial nerve and it inhibits the role of the latter.

The trigeminal nerve, which also controls the respiratory centers in the pontine tegmentum by its sensory nucleus, promotes restoration of nasal breathing, allowing the posterior part of the tongue to adopt an elevated posture (a lingual dome).Similarly, contraction of the tensor tympani muscle of the hammer, which is innervated by the trigeminal nerve, allows the middle ear to be ventilated by dilation of the Eustachian tube, thereby reducing serous otitis problems.

Figure 1. The icon for suction-deglutition is activated by the facial nerve: "my lips are spread, my teeth are not touching each other".

**Figure 2.** The icon for dentition-type deglutition: "my lips are pursed, my molars in occlusion" is activated by the trigeminal nerve, which not only allows molar occlusion but also protects the tongue from being bitten due to the abundance of trigeminal nerve endings in its epithelial lining.

Figure 3. Contrary to what speech therapists recommend, it is not the apical part of the tongue that needs to gain the child's attention but the posterior part. Obsessed with the sensory search for the retro-incisive papilla, the child risks raising the lingual apex, leading to a lowering of the posterior part that will prevent engagement of the styloglossus, which is the levator muscle of the lingual dome [6].


**Figure 4.** Worn for 15 min per day while watching television, Froggy Mouth® allows relaxation of all of the anterior facial muscles.

Control can be transferred to the parents, who need to take note of the labial posture five times per day and congratulate or correct the child. These two actions are not similar, as they involve the cortico-cortical circuits that traverse the basal ganglia and the cortico-cortical circuits that traverse at the level of the cerebellum.

The work by Robert Bjork (UCLA) affirms that the number of monitoring sessions is more important than the number of learning sessions for engrammation of a new pattern. This requirement for inhibition of the wrong circuit is fundamental to automatization of the correct program.

## Learning is Eliminating

Only Froggy Mouth® allows this double action: by only controlling the labial posture it allows postural alteration of the tongue and the pharyngeal-velar muscles by a cross-talk effect. "This dual posterior and occlusal functional lingual necessity, too often forgotten by re-educators of oral functions, is likely one of the causes of the too frequent failures of re-educations" (Delaire) [5]. Wearing a Froggy Mouth® from 3 years of age onward does not present any contraindications. It is compatible with all types of orthodontic devices in adolescents and is still effective in adults (neurogenesis or enrichment of the extensions of existing neurons). It also allows intervention in the re-education of disabled children.

## Conclusions

Re-education can be based on two different approaches: a bottom-up approach that directly targets the deficit or the anomaly, but that does not require becoming aware of this deficit or anomaly, and a top-down approach that aims to generate awareness of the deficit or of this anomaly and the explicit acquisition of new corrective or compensatory strategies.

Early normalization of orofacial functions allows prevention to be approached at its three stages irrespective of the selected technique are preventing deformations from occurring, once they have occurred, preventing them from becoming worse, once corrected, preventing them from recurring.

## References

1. Patrick F. Orthodontie précoce en denture temporaire Cdp. 2003.
2. Jean-Pierre C. L'homme neuronal Fayard. 1983.
3. Gérard C. Les oralités humaines Doin. 2010.
4. Gérard C. Oralité du fœtus Sauramps Médical. 2015.
5. Arthur G. Neurosciences. Piccin. 1996.
6. Eric K. A la recherche de la mémoire. Odile Jacob. 2011.
7. Patrick F, Waddah S, Lalauze-Pol R. De la dysfonction à la dysmorphose. Apport de Froggy mouth. Edition Orthopolis.2016.
8. Fournier M, Girard M. Acquisition and sustainment of automatic reflexes in maxillofacial rehabilitation. Orthod Fr. 2013; 84: 287-294.

To cite this article: Fellus P. How biochemistry and neurophysiology are involved in the re-education of deglutition. Japan Journal of Medicine. 2018: 2:1.

SCIENTIFIC ARCHIVES OF DENTAL SCIENCES

Volume 2 Issue 6 June 2019

Case Study

# Swallowing Rehabilitation in a Child with Narcolepsy and Cataplexy

**Fellus Patrick[1]* and Lecendreux Michel[2]**

[1]*Président of the French Pediatric Orthodontic Society, France*

[2]*Reference Centre for narcolepsy at University Hospital Robert-Debré in Paris, France*

***Corresponding Author:** Fellus Patrick, Président of the French Pediatric Orthodontic Society, France.

**Received:** May 16, 2019

## Abstract

Narcolepsy with cataplexy is a rare and highly debilitating neurological disorder characterized by excessive daytime sleepiness, sleep attacks and cataplexy which correspond to sudden loss of muscle strength and preserved consciousness and are mainly triggered by positive emotions such as laughter or excitement or telling a joke). Cataplexy may range from a slackening of the facial muscles that is barely perceivable to a drop of the jaw or head, weakness in the neck, shoulders, knees or total collapse.

A high number of pediatric cases are diagnosed and treated at the Reference Centre for narcolepsy at University Hospital Robert-Debré in Paris.

**Keywords:** Swallowing Rehabilitation; Child; Narcolepsy; Cataplexy

## Introduction

It is of interest to observe that, among all the patients examined in an orthodontic setting, 50% failed to show abnormalities whereas deformations were major in the other half. Questioning the parents revealed that when occlusion was correct at the time when the first symptoms of the disease were expressed, no doubt related to physiological swallowing, there was no occlusal modification. On the other hand, pre-existing dysmorphic features were almost systematically worsened [1-3].

## Case Study and Discussion

Related attention-deficit disorders make rehabilitation difficult, with a high rate of failure.

All conventional rehabilitation approaches involving increased awareness of the gestures performed and then of the gestures to be performed are doomed to failure, especially as only a very large number of repetitions could manage to engram the new practice in the long-term memory.

There was major incisive open bite, but it regressed progressively, reaching normal conditions of occlusion in 18 months.

The patient is very absent-minded and does not feel concerned with her therapy and the very wide gap related to her tongue dysfunctions must be treated.

She did, however, accept to wear the Froggymouth for 15 minutes a day while watching television. The limbic system will assimilate this fun activity with a reward, a decisive element in automation. Placed at a distance from the receiver, the gaze is horizontal as is the lingual plane. Once the device is installed, she can no longer swallow her saliva with her usual programme, but swallowing is a vital function that will lead to an immediate reaction in the brain stem to find another muscle dynamic to be able to swallow. The patient continues to watch her programme and doesn't even notice these changes; as the facial nerve's activity is inhibited the trigeminal nerve takes over, facilitating dental occlusion, and the styloglossus comes into play for the physiological progression of the swallowing programme in a subject with teeth.



***Figure 1:*** *Related attention-deficit disorders.*

***Figure 2:*** *Open bite at the beginning of the treatment.*

***Figure 3:*** *Six month later.*

***Figure 4 and 5:*** *15 month later.*

## Conclusion

This bottom-up approach can be used successfully in children with sensory-motor disabilities. Froggymouth is the best approach to rehabilitating these children The effectiveness of this approach will, of course, be greater in children with no particular problems,

starting at age 4; it could even be proposed to adults, more than 30% of whom have atypical swallowing and whose work does not leave them enough time to undertake rehabilitation over several months.

## Bibliography


1. Bear Mark F, Connors Barry W, Paradiso Michael A. Neurosciences. À la découverte du cerveau. Ed. Pradel, 4th édition: 2016.
2. Fellus Patrick. Neurosciences et rééducation de la déglutition. Froggymouth une voie anoétique, Editions Orthopolis: 2019.
3. Houde Olivier. L'intelligence humaine n'est pas un algorithme. Editions Odile Jacob: 2019.


**Volume 2 Issue 6 June 2019**

# Froggy mouth: a new myofunctional approach towards atypical swallowing

S. Di Vecchio*, P. Manzini**, E.Candida***, Gargari M.****

*Department of Dentistry Hospital San Pietro F.B.F., Rome, Italy
**Department of Maxillofacial Unit, Neuroscience, Carlo Poma Hospital, Mantova, Italy
***Private practice Rome, Italy
****Department of Clinical Sciences and Translational Medicine, University of Rome "Tor Vergata", Rome, Italy

## Abstract

**Introduction** Atypical swallowing has a high incidence in adult and child populations. The treatment of the latter is generally achieved by the adoption of orthodontic appliances in conjunction with speech therapy. The aim of this article is to describe the clinical protocol of Froggy Mouth, an innovative myofunctional appliance designed to correct the atypical swallowing.

**Materials and m ethod** The Froggy Mouth appliance has been tested by the authors Di Vecchio at the Orthognatodontics department of Fatebenefratelli San Pietro Hospital in Rome, Italy, and by Manzini at the Orthodontics department of Carlo Poma Hospital in Mantova, Italy. This article will illustrate the clinical protocol of the appliance with therapeutic indications, clinical phases, instruction and patients and parents motivation and follow-up results.

**Results** Froggy Mouth has proven effective in the correction of atypical swallowing, from both the clinical and the functional standpoints. The fastest and most predictable results were obtained in patients during their physiological developmental age. This appliance, compared to the traditional logopaedic therapy, requires less commitment in terms of time for the patient (only 15 minutes per day), with more predictable and durable results over time.

**Conclusions** The clinical evidences indicate that the Froggy Mouth is effective in the myofunctional correction of the atypical swallowing mechanism, providing the clinician a new therapeutic approach for neuromuscular re-training of atypical deglutition and dysfunctional deglutition in patients during their growth phase. However, further scientific evidences are needed to support the results of this investigation.

KEYWORD Atypical swallowing, Froggy Mouth, Myofunctional appliance, Open bite, Orthodontics, Speech therapy.

## Introduction

Atypical swallowing is a myofunctional problem, characterised by an altered lingual posture during swallowing. Primary infantile deglutition develops around the 12th week of intrauterine life and it is characterised by a forward tongue posture [Bernandi et al., 2013] and contraction of the perioral muscles [Tecco et al., 2015] (orbicular and buccinator), leading to a higher negative pressure in the oral cavity. In normal conditions, around the age of 3 and with the development of alternate unilateral mastication [Mummolo et al., 2014], the infantile deglutition pattern changes into a so-called mature deglutition pattern [Condò et al., 2012].

During adult or mature swallowing, dental arches are in contact and tongue is elevated, resting in the posterior-superior part of the palatine vault [Suàrez et al., 2014]. During this phase the tongue pressure stimulates the anteroposterior and transversal growth of the maxilla [Eichenberger et al., 2014; Mummolo et al., 2014]. If transition from the infantile to the adult swallowing does not take place, the former triggers a pathological mechanism, defined as atypical swallowing [Giuca et al., 2008].

The aetiology is multifactorial.

- Altered lifestyle such as prolonged bottle feeding, late weaning, consistency of food (lack of solid food).
- Bad habits such as finger or dummy sucking, onycophagy, labial interposition.
- Respiratory problems such as oral breathing, adenoid hypertrophy, tonsillar hypertrophy, rhinitis, bronchial asthma.
- Congenital oral anomalies (short lingual frenulum or ankyloglossy).

Atypical deglutition is frequently correlated with the following.

- Dental malocclusions [Tecco et al., 2014]: proclined maxillary anteriors, increased overjet, openbite, flaring and spaced dentition.
- Skeletal malocclusions [Tecco et al., 2011]: sagittal and transversal discrepancies with a narrow and protruded maxillary arch, mandibular retroposition.

The high prevalence of malocclusions related to atypical swallowing makes this a subject of strong interest in scientific

researches. Because of the multifactorial aetiopathogenesis, high incidence and the correlation with dento-skeletal malocclusions, this topic is not only very interesting for clinicians, but is also strongly debated among healthcare providers. A literature review on this subject confirms that orthodontic treatment alone is not sufficient to solve the problem in patients with atypical swallowing. This requires a multidisciplinary therapy, orthodontic and myofunctional approach, to ensure optimal and long-lasting results [Maspero et al., 2014].

To obtain an adequate myofunctional correction [Mummolo et al., 2014] of atypical swallowing has been treated with appliances such as palatal tongue crib, fixed or removable, the Tucat pearl or speech therapy exercises, requiring a high compliance from the patient, and giving unpredictable and unstable results.

Eric Kandel, Nobel-prize winner in 2000, in his research on the physiological basis of memory storage in neurons has proved that new information is acquired and stored promptly, because the memory cerebral systems are easily modifiable. His studies have proven that when working on subconscious levels it is important not just the duration of treatment but also consistency. Synaptic connections in varius brain circuits can be reinforced or slowed down by the engrammatic mechanism and mnemonic traces formed during the learning process and experience, determining in this way definitive biochemical and structural changes [Kandel, 2007].

The learning process occurs through:

- Voluntary pathway, with the stimulation of cortical zones causing synaptic excitation only;
- Involuntary pathway, with modification of synapses structure and increase in their numeric value (permanent stabilisation of new acquisitions); here stimulation origins from the subcortical region, in which automatisms are developed.

Following Kandel's research, Patric Fellus (expert in Dentofacial Orthopaedics) designed the Froggy Mouth appliance, which triggers the involuntary pathway, inhibiting bilabial contact and eliminating negative pressure inside oral cavity, enabling the tongue to protrude and retract through styloglossus muscle contraction, thus achieving proper deglutition. Fellus states that the attention of the patient should not be focused on tongue tip, as it usually happens during myofunctional therapy, but on the posterior portion of the tongue. The patient, engaged in tongue tip elevation trying to reach the retroincisal papilla, triggers a lower position of the posterior portion of the tongue, inhibiting elevation of the posterior portion of the tongue by styloglossus muscle action, which would consequently place the tongue tip in its physiological position [Fellus, 2006; Fellus, 2014; Fellus, 2016; Ortu et al., 2016].

The aim of this article is to describe the clinical protocol of Froggy Mouth, an innovative and simple myofunctional appliance used in order to solve atypical swallowing and to allow myofunctional correction of altered tongue position. Benefits and limits of this appliance will be confronted with the traditional logopaedic therapy and other appliances traditionally used for the resolution of this condition.

FIG. 1 Froggy Mouth is a small removable appliance.

## Materials and methods

The Froggy Mouth appliance has been tested in 370 patients at the Orthognatodontics Department of Fatebenefratelli San Pietro Hospital in Rome and at the Orthodontics department of Carlo Poma Hospital in Mantova (Italy).

Froggy Mouth is a small removable appliance made of a flexible thermoplastic elastomer, without latex or phthalates. It is available in 3 sizes of different colour orthoboxes S (Blue), M (red) and L (Violet) (Fig. 1). The appliance has a small stamped letter in the inferior portion and a dot in the superior portion. In order to choose the right size, the appliance has a specific dedicated caliber. The Froggy Mouth should be positioned between the lips and the teeth leaving about 2 mm from the labial commisure on both sides.

The Froggy Mouth should be used 15 minutes every day (in order to activate the neural circuits that generate the automatic movements controlled by the trigeminal nerve) always during a playful activity (in order to activate the lymbic system that facilitates and accelerates the learning process) [Kandel, 2007]: preferably watching TV, while playing videogames or using the computer. The protocol requires to maintain a correct head position parallel to the floor.

Indications of Froggy Mouth are: atypical sawllowing, tongue interposition between dental arches, anterior and posterior openbite, trasversal contraction, anterior or posterior crossbite, increased overjet, proclined front teeth, deep bite, mandibular protrusion, dyslalia, bruxism, posture alteration, oral breathing and adenoid disorders,snoring, drooling.

Before delivery of the appliance, the following was required:

1) Filling of the Clinical record (Fig. 2-4).

This ad hoc Clinical record was created in collaboration

**Clinical record**

Date___/___/___

Operator _____

Surname _____ Name _____ Birth Date _____
Birth Place _____ Address _____
Tel _____ Cell _____ e-mail _____

Clinical Exam

**Dentition** Deciduous ☐ Mixed ☐ Permanent ☐

**Skeletal characteristics** Class I ☐ Class II ☐ Class III ☐

**Dental class** Class I ☐ Class II ☐ Class III ☐

**Maxillary contraction** Anterior cross ☐ Lateral Cross ☐

Deepbite ☐ Openbite ☐ Overjet ☐

**Temporomandibular clicking or pain** Yes ☐ No ☐

**Requested Rx exams** OPT ☐ LatCeph ☐ PA Ceph ☐

ENT diagnosis

| | | |
|---|---|---|
| TONSILLECTOMY | YES WHEN: | NO |
| ADENOIDECTOMY | YES WHEN: | NO |
| CRANIOFACIAL TRAUMA | YES | NO |
| EARACHE | YES | NO |
| BREATHING DIFFICULTIES | YES | NO |
| FREQUENT RHINITIS | YES | NO |
| FREQUENT OTITIS | YES | NO |
| TONSILLITIS | YES | NO |
| RHINOPHARYNGITIS | YES | NO |
| OPEN MOUTH RESTING POSTURE | YES | NO |
| THUMB SUCKING/OTHER | YES | NO |

FIG. 2 Clinical record.

with different health care providers that followed this group of patients during their growth phase (logopaedists, ostheopathic doctors, allergologists).

2) Collection of intraoral and extraoral photos of the patients (Fig. 5, 6), impressions, ortopantomographs and lateral cephalograms.
3) Instructions were given to patients and their parents; motivated to maintain a proper hygiene.
4) Follow-up appointments were scheduled every 6–8 weeks, and the orthodontist established the duration of treatment based on the clinical results.
5) At the follow-up appointments, intraoral and extraoral photos were taken. Patients or guardians were asked to fill in a treatment progress questionnaire, in order to evaluate the response to the treatment (Table 1).

This questionnaire is very important because it helps clinicians to record data that can not be observed during the follow-up appointment (i.e. snoring, sleeping with mouth open, sleep apnoea, somnambulism, etc.).

## Results

Froggy Mouth resulted effective in the correction of atypical swallowing. This appliance showed positive clinical results in resolving malocclusions such as open bite (Fig. 7), transverse palatal contraction, cross bite (Fig. 9) and deep bite (Fig. 10) in patients during their physiological growth phase. From the evaluation of the treatment progress questionnaire, it can be observed that the Froggy Mouth helped in resolving other issues such as snoring, drooling, sleep apnoea, and difficulty breathing through nose (Table 2). Extraoral photos (Fig. 11) show the change in the face, neck and shoulder

| | | |
|---|---|---|
| INFERIOR LIP SUCKING | YES | NO |
| SLEEPS WITH THE MOUTH OPEN | YES | NO |
| SNORING | YES | NO |
| EYE BAGS | YES | NO |
| NOCTURNAL SWEATING | YES | NO |
| DIFFICULTIES IN WAKING UP IN THE MORNING | YES | NO |
| NOCTURNAL ENURESIS | YES | NO |
| CHAPPED LIPS | YES | NO |
| NIGHTMARES | YES | NO |
| SLEEPWALKING | YES | NO |
| TALKS DURING SLEEP | YES | NO |
| FREQUENT NOCTURNAL WAKE UPS | YES | NO |
| SALIVA STAINS ON PILLOW | YES | NO |
| SLEEP APNEA | YES | NO |
| THE CHILD POSITIONS THE TONGUE FORWARD WHILE SPEAKS OR SWALLOWS | YES | NO |
| HYPERACTIVITY | YES | NO |
| TROUBLE CONCENTRATING | YES | NO |

SPEECH DIAGNOSIS

| |
|---|
| |
| |
| |

NEUROLOGICAL DIAGNOSIS

| | | |
|---|---|---|
| CEREBROVASCULAR DISEASE | YES | NO |
| POSTURAL AND MUSCLE TONE DISTURBANCES | YES | NO |
| DYSTONIAS | YES | NO |
| HEADACHES | YES | NO |

FIG. 3 Clinical record.

| | | |
|---|---|---|
| PROBLEMS DURING BIRTH (HYPOXIA) | YES | NO |
| MULTIPLE TICS | YES | NO |
| OTHER | YES | NO |

ORTHOPAEDIC AND POSTUAL DIAGNOSIS

| | | |
|---|---|---|
| TORTICOLLIS | | |
| EVIDENT POSTURAL ASYMMETRIES | | |
| FLAT HEAD SYNDROME | | |
| ORTHOPAEDIC VISITS OR TREATMENTS | | |
| IF YES, WHY? | | |
| PHYSICAL THERAPY VISITS OR TREATMENTS | | |
| IF YES, WHY? | | |
| PSYCHOMOTOR VISITS OR TREATMENTS | | |
| IF YES, WHY? | | |
| OTHER | | |

ALLERGIC DIAGNOSIS

| |
|---|
| |
| |
| |

ORTHODONTIC THERAPEUTIC PLAN

| |
|---|
| |
| |
| |

*USE OF FROGGY MOUTH APPLIANCE*

- AS UNIQUE APPLIANCE ☐
- AS SUPPORT IN ORTHOPHONIC RETRAINING ☐
- COADJUVANT IN THE ORTHODONTICTHERAPY ☐

FIG. 4 Clinical record.

FIG. 5 Collection of intraoral photos of patients.

position immediately after wearing the device. These clinical results can point out a direct correlation between an altered contraction of perioral and masticatory musculature and an asymmetrical contraction of cervical musculature, with TMJ and posture implications [Saccomanno et al., 2014; Ortu et. al., 2018]. This requires a good cooperation with

FIG. 6 Collection of extraoral photos of patients.

| | FIRST CONTROL AT 3 MONTHS | | SECOND CONTROL AT 6 MONTHS | | THIRD CONTROL AT 9 MONTHS | |
|---|---|---|---|---|---|---|
| - THE CHILD REFERS EARACHE? | Yes | No | Yes | No | Yes | No |
| - KEEPS HAVING DIFFICULTIES BREATHING? | Yes | No | Yes | No | Yes | No |
| - STAYS WITH THE MOUTH OPEN DURING THE DAY? | Yes | No | Yes | No | Yes | No |
| - KEEPS SUCKING THE FINGER? | Yes | No | Yes | No | Yes | No |
| - KEEPS SUCKING THE PACIFIER? | Yes | No | Yes | No | Yes | No |
| - KEEPS SUCKING THE INFERIOR LIP? | Yes | No | Yes | No | Yes | No |
| - KEEPS SLEEPING WITH THE MOUTH OPEN? | Yes | No | Yes | No | Yes | No |
| - KEEPS SNORING? | Yes | No | Yes | No | Yes | No |
| - SHOWS EYE BAGS? | Yes | No | Yes | No | Yes | No |
| - KEEPS SWEATING AT NIGHT? | Yes | No | Yes | No | Yes | No |
| - HAS DIFFICULTIES IN WAKING UP IN THE MORNING? | Yes | No | Yes | No | Yes | No |
| - HAS NOCTURNAL ENURESIS? | Yes | No | Yes | No | Yes | No |
| - HAS CHAPPED LIPS? | Yes | No | Yes | No | Yes | No |
| - REFERS NIGHTMARES? | Yes | No | Yes | No | Yes | No |
| - THE PATIENT SLEEPWALKS? | Yes | No | Yes | No | Yes | No |

| | | | | | | |
|---|---|---|---|---|---|---|
| - PATIENT TALKS DURING SLEEP? | Yes | No | Yes | No | Yes | No |
| - PATIENT REFERS FREQUENT NOCTURNAL AWAKENINGS? | Yes | No | Yes | No | Yes | No |
| - YOU NOTE STAINS OF SALIVA ON THE PILLOW? | Yes | No | Yes | No | Yes | No |
| - THE PATIENT HAS NOCTURNAL APNEAS? | Yes | No | Yes | No | Yes | No |
| - THE PATIENT PUTS THE TONGUE BETWEEN THE ARCADES WHEN SPEAKING/SWALLOWING? | Yes | No | Yes | No | Yes | No |
| - THE PATIENT IS HYPERACTIVE? | Yes | No | Yes | No | Yes | No |
| - THE PATIENT HAS DIFFICULTIES IN CONCENTRATING? | Yes | No | Yes | No | Yes | No |
| - THE PATIENT REFERS MUSCLE TONE DISTURBANCES? | Yes | No | Yes | No | Yes | No |
| - THE PATIENT REFERS HEADACHES? | Yes | No | Yes | No | Yes | No |

TABLE 1 - TABLE 2 In order to evaluate the response to the treatment, a treatment progress questionnaire was administered.

FIG. 7 Case 1 age 8, female, altered tongue posture, open bite, atypical swallowing Before (A), at 4 months (B), after 6 months (C).

FIG. 8 Case 2 age 8, male, altered tongue posture, open bite, atypical swallowing. Before (A, B, C), at 6 months (D, E, F).

FIG. 9 Case 3 age 7, male, altered tongue posture, crossbite, atypical swallowing. Before (A, B, C), at 6 months (D, E, F).

FIG. 10 Case 4 age 8, ternale, altered tongue posture, deepbite, atypical swallowing.Before (A, B, C), at 8 months (D, E, F).

FIG. 11 Extraoral photos showing the change in the face, neck and shoulder position after wearing the device.

the osteopath, to monitor and elaborate these early results [Ottria et al., 2018; Ottria et al., 2018; Ottria et al., 2018]. The device also requires less compliance from the patient (only 15 minutes per day) compared to traditional speech therapy alone and, as established by the studies of Kandel [2007], the results are more predictable and long-lasting.

## Conclusions

Clinical evidences indicate that the clinical protocol of Froggy Mouth is effective in the myofunctional correction of the atypical swallowing mechanism, providing the clinician a new therapeutic approach for atypical swallowing and dysfunctional deglutition in patients during their growth phase. However, it should be underscored that the concomitant speech therapy is crucial for faster and effective results. However, further scientific evidence should support these early results.

## References


- Bernardi S, Zeka K, Mummolo S, Marzo G, Continenza MA. Development of a new protocol: a macroscopic study of the tongue dorsal surface. It J Anatom Embriol 2013; 118(2):24.
- Tecco S, Baldini A, Mummolo S, Marchetti E, Giuca MR, Marzo G, Gherlone EF. Frenulectomy of the tongue and the influence of rehabilitation exercises on the sEMG activity of masticatory mucles. J Electromyogr Kinesiol 2015; 25(4):619-628.
- Mummolo S, Ortu E, Necozione S, Monaco A, Marzo G. Relationship between mastication and cognitive function in elderly in L'Aquila. Int J Clin Exp Med 2014; 7(4):1040-6.
- Condò R, Costacurta M, Perugia C, Docimo R. Atypical deglutition: diagnosis and interceptive treatment. A clinical study. Eur J Paediatr Dent 2012; 13(3):209-14.
- Suàrez C, Antonarakis GS, Pham D. Occlusal characteristics in subjects with or without the ability to roll the tongue. Eur J Paediatr Dent 2014; 15(2):147-150.
- Eichenberger M, Baumgartner S. The impact of rapid palatal expansion on children's general healt: a literature review. Eur J Paediatr Dent 2014; 15(1):67-71.
- Mummolo S, Marchetti E, Albani F, Campanella V, Pugliese F, Di Martino S, Tecco S, Marzo G. Comparison between rapid and slow palatal expansion: evaluation of selected periodontal indices. Head Face Med 2014; 10:30.
- Giuca MR, Pasini M, Pagano A, Mummolo S, Vanni A. Longitudinal study on a rehabilitative model for correction of atypical swallowing. Eur J Paediatr Dent 2008; 9(4):170-4.
- Tecco S, Lacarbonara M, Dinoi MT, Gallusi G, Marchetti E, Mummolo S, Campanella V, Marzo G. The retrieval of unerupted teeth in pedodontics: two case reports. J Med Case Rep 2014; 8:334.
- Tecco S, Mummolo S, Marchetti E, Tetè S, Campanella V, Gatto R, Gallusi G, Tagliabue A, Marzo G. sEMG activity of masticatory, neck, and trunk muscles during the treatment of scoliosis with functional braces. A longitudinal controlled study. J Electromyogr Kinesiol 2011; 21(6):885-92.
- Maspero, C., et al. Atypical swallowing: a review. Minerva Stomatol 2014 63(6): 217-227.
- Mummolo S, Tieri M, Tecco S, Mattei A, Albani F, Giuca MR, Marzo G. Clinical evaluation of salivary indices and levels of Streptococcus Mutans and Lactobacillus in patients treated with Occlus-o-Guide. Eur J Paediatr Dent 2014; 15(4):367-70.
- Kandel E. Alla ricerca della memoria. La storia di una nuova scienza della mente 2007, Codice edizioni, Torino.
- Felus P. Dysfuctions linguale et dysmorphies Orthod Fr 2006; 77: 105-12
- Fellus P. Succion et dèglutition Revue d'Orthopedie Dentofacial 2014; vol 48; 4 : 425-8
- Fellus P. De la succion-dèglutition à la dèglutition du subject dentè Orthod Fr 2016; 87: 89-90
- Ortu E, Lacarbonara M, Cattaneo R, Marzo G, Gatto R, Monaco A. Electromyographic evaluation of a patient treated with extraoral traction:a case report. Eur J Paediatr Dent 2016; 17(2):123-128.
- Saccomanno S, Antonini G, D'Alatri L, D'Angeloantonio M, Fiorita A, Deli R. Case report of patients treated with an orthodontic and myofunctional protocol. Eur J Paediatr Dent 2014; 15(2):184-186.
- Ortu E, Pietropaoli D, Marchetti E, Marchili N, Marzo G, Monaco A. Bruxism in children: use of the Functional Plane of Monaco (FPM). Eur J Paediatr Dent 2018; 19(4):287-294
- Ottria L, Candotto V, Guzzo F, Gargari M, Barlattani A. "Temporomandibular joint and related structures: anatomical and Histological aspects". J Biol Regul Homeost Agents. 2018 Jan-Feb;32(2 Suppl. 1):203-207.
- Ottria L, Lauritano D, Guzzo F, Gargari M, Barlattani A. "Anatomic relationship between temporomandibular joint and middle ear". J Biol Regul Homeost Agents. 2018 Jan-Feb;32(2 Suppl. 1):209-212.
- Ottria L, Candotto V, Guzzo F, Gargari M, Barlattani A. "TMJ's capsule histological and macroscopical study: relationship between ligamentous laxity and TMI dysfunctions". J Biol Regul Homeost Agents. 2018 Jan-Feb;32(2 Suppl. 1):213-216.

MORE INFORMATION:

www.froggymouth.it

info@atfcsrl.com